

REVIEW: NON-*HELICOBACTER PYLORI* HELICOBACTER

M. Nakamura¹, S.Y. Murayama², E. Rimbara³

¹Omura Satoshi Memorial Institute, Kitasato University, Tokyo, Japan

²Department of Fungal Infection, National Institute of Infectious Diseases, Tokyo, Japan

³Department of Bacteriology II, National Institute of Infectious Diseases, Tokyo, Japan

Corresponding Author: M. Nakamura, MD; email: mngast@mac.com

Abstract – This article reviews the most important and relevant literature published between April 2021 and March 2022 on non-*Helicobacter pylori* Helicobacter (NHPH) infections in humans and animals. Of note, *Helicobacter delphinicola* was newly described in this period. The first part of this review focuses on the literature describing gastric NHPH. Many clinical reports have been published, especially those regarding *Helicobacter suis* with chronic gastritis, gastric mucosa-associated mucosal tissue (MALT) lymphoma, and gastric cancer, which are topics of major clinical interest. The relation of NHPH to neurological diseases in humans, including Parkinson's disease, is an ongoing problem, and glycan-mediated adhesion of *H. suis* in acidic conditions is an intriguing topic. Enterohepatic Helicobacter infections are associated with colorectal, hepatic, and breast cancers, as well as alcohol-related liver diseases in animal models. *Helicobacter cinaedi* bacteraemia has been reported to be related to aortic aneurysm, *Legionella* pneumonia, and chronic subdural haematoma, and the Bactec Fx system has been demonstrated as useful for these investigations. PCR experiments have given clues on the relationship between Helicobacter bilis and pancreatobiliary cancer, and its pathogenesis by the cytolethal distending toxin, has been demonstrated by functional analysis of protein products.

Keywords: Non-*Helicobacter pylori* helicobacter, Human disease, Animal model, Pathogenesis.

RECENTLY DISCOVERED NON-*HELICOBACTER PYLORI* HELICOBACTER

During this period, another species, *Helicobacter delphinicola*, was added to the genus *Helicobacter*, bringing the total number of species to 46. A phylogenetic tree is presented (Figure 1) based on the *List of Prokaryotic names with Standing in Nomenclature* as of May 2, 2022.

Gastritis and gastric ulcers are well-recognised illnesses in cetaceans, and the genus *Helicobacter* is considered to be the main cause. *H. delphinicola* strains were isolated from the gastric fluid of captive common bottlenose dolphins *Tursiops truncatus*¹. These novel isolates were resistant to 2% NaCl. The culture supernatant of some isolates induced intracellular vacuolisation in cultured mammalian cells resembling the vacuolating toxin in *Helicobacter pylori* and could be one of the pathogenetic factors of gastric diseases in dolphins, in addition to *Helicobacter cetorum*, a former candidate.

GASTRIC NON-*HELICOBACTER PYLORI* HELICOBACTER INFECTIONS IN HUMAN GASTROINTESTINAL DISEASES

It has been indicated that non-*Helicobacter pylori* Helicobacter (NHPH) infections are associated with chronic mild gastritis, nodular gastritis, gastroduodenal ulcers, and gastric mucosa-associated



This work is licensed under a [Creative Commons Attribution-NonCommercial-ShareAlike 4.0 International License](https://creativecommons.org/licenses/by-nc-sa/4.0/)

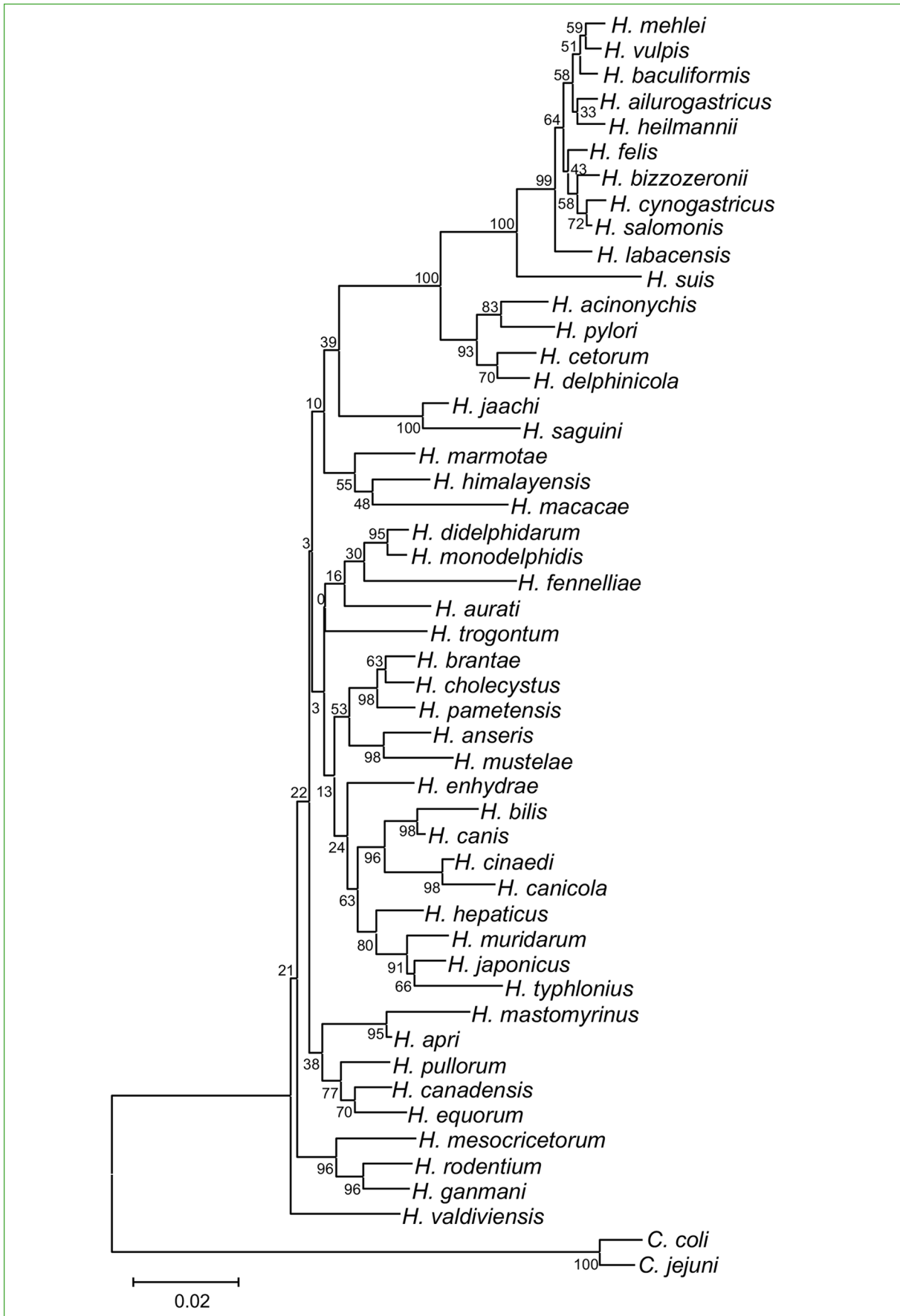


Figure 1. Phylogenetic tree of *Helicobacter* species based on 16S rRNA gene.

lymphoid tissue (MALT) lymphoma. Several NHPH-positive gastric cancer cases have been reported sporadically, however, their common characteristics remained unreported until recently. Over the past 12 months, several reports concerning gastroduodenal diseases have been published (Table 1).

In an investigation on chronic gastritis, NHPH gastritis was found in 50 of 3,847 patients (1.30%)². The prevalence increased to 3.35% (30 of 896 patients) in the latter 2 years and 4 months, with increasing recognition of its characteristic endoscopic findings for the diagnosis². PCR was performed on 30 patients with gastritis using endoscopically obtained gastric mucosa, detecting NHPH in 28 of them: 26 with *Helicobacter suis* and 2 with *Helicobacter heilmannii*/*Helicobacter ailurogastricus*. We must be careful not to speak of prevalence, because it refers to patients with gastritis and not to the general population, where the actual prevalence should be several times lower.

Endoscopic findings of NHPH-induced gastritis have been analysed³ and cracked mucosa, spotty redness, nodular gastritis-like appearance, and white marbled appearance were observed in multiple cases. Clarifying these characteristics may provide indicators of NHPH infection before the final proof of infection by PCR and immunohistochemical studies.

Some unusual cases have been reported in research⁴ on gastroduodenal ulcers and acute gastric mucosal lesions. In the former, a patient presented with acute onset abdominal pain secondary to acute antral and duodenal ulcers in the second portion of the duodenum, which was caused by *H. heilmannii*. The patient underwent successful treatment consisting of 40 mg pantoprazole, 1 g amoxicillin, and 500 mg clarithromycin, all b.i.d. for two weeks, although this diagnosis was made only by immunohistochemistry for all Helicobacters and the patient was taking aspirin, suggesting that this lesion may have been induced by NHPH or aspirin.

The fourth reported case so far of acute gastric ulcer caused by NHPH was reported after PCR⁵. This report showed that NHPH can induce acute gastric lesions and showed the effective eradication of NHPH by proton pump inhibitor (PPI) monotherapy instead of a combination of antibiotics and acid suppressants.

In another case, a 46-year-old dog owner was reported to have multiple NHPH-related non-bleeding duodenal erosions, for which *H. heilmannii* was identified only by histology⁶.

Eradication therapy was performed as a first-line treatment for 182 cases of gastric MALT lymphoma, classified according to *H. pylori* infection and API2-MALT1 mutation status⁷. The API2-MALT1 mutation was observed in 13 of 182 patients (7.1%), none of whom were cured by eradication therapy. *H. pylori*-negative patients had a significantly higher NHPH infection rate than *H. pylori*-positive patients [16/29 (55%) vs. 3/29 (10%); $p < 0.05$]. Among the *H. pylori*-negative cases, NHPH-positive cases had a significantly higher complete response rate than NHPH-negative cases (12/16 (75%) vs. 3/13 (23%); $p < 0.05$), showing that MALT lymphoma induced by NHPH was very responsive to eradication therapy used for *H. pylori*.

TABLE 1. REPORTS ON GASTRODUODENAL DISEASES.

NHPH-related gastroduodenal diseases reported during this period	Ref number
Acute gastric mucosal lesion (acute gastric ulcer)	5
Duodenal erosion	6
Gastroduodenal ulcer (second portion of duodenum)	4
Chronic gastritis	2, 3
Gastric cancer	8
MALT lymphoma	3, 7
Gastric hyperplastic polyp	11
Dyspepsia	5

One case of gastric MALT lymphoma showed the aspect of multiple polyps that were positive for both *H. pylori* and *H. suis*, as assessed by PCR8. Eradication therapy was successful, and the lymphoma cells disappeared.

Although there have been sporadic reports on the relationship between NHPH and gastric cancer, there has been no cohesive analysis and no clear conclusions have been reached. PCR analysis of NHPH and *H. pylori*, as well as immunohistochemistry using anti-*H. suis* antibodies⁸, were performed on samples from 282 Korean gastric cancer patients, of whom three patients (1.1%) were positive for NHPH⁹. One patient was positive for both *H. pylori* and NHPH, another patient was positive for *H. pylori*-specific serum IgG, while the other patient showed no evidence of *H. pylori* infection. All three NHPH-positive gastric cancers, two of which belonged to *H. suis* by immunohistochemistry, were located in the antrum and all were well-differentiated adenocarcinomas, while one case was also positive for *H. pylori* by PCR, and the other case was positive for *H. pylori* by serology. This suggested that gastric NHPH could be a cause of gastric cancer. However, other reports found that NHPH-induced gastritis rarely induces gastric mucosal atrophy and intestinal metaplasia, while undifferentiated gastric cancer is supposed to be strongly related to NHPH¹⁰. Further studies are required to clarify these observations.

Regarding other gastric diseases, the pathological and immunohistochemical localisation of *H. suis* was investigated in hyperplastic polyps, which are generally thought to be associated with *H. pylori* or autoimmune gastritis¹¹.

GASTRIC NON-HELICOBACTER PYLORI/HELICOBACTER INFECTIONS ASSOCIATED WITH HUMAN NEUROLOGICAL DISEASES

Recent studies¹² have suggested a link between *H. pylori* as well as *H. suis*, and neurological disorders. A high prevalence of *H. suis* has been reported in patients with Parkinson's disease, and gastric *H. suis* infection was shown to affect the homeostasis of mouse brains. The mechanism is still unknown, but the gut microbiota can communicate with the brain *via* several routes, collectively called the microbiome–gut–brain axis: neuronal, endocrine, metabolic, and immunological routes. In contrast, gastric *H. suis* infection unexpectedly protected, at least partially, against 6-OHDA-induced dopaminergic cell loss and motor function impairment in a unilateral intrastriatal 6-OHDA PD mouse model¹³. This protective effect may be explainable by *H. suis*-mediated changes in gene expression related to the reduction of oxidative stress. Specifically, brain tissue gene expression changes in the Nrf2 pathway and endogenous peroxidases have been shown to act in parallel with the observed neuroprotective effect of *H. suis*. This study adds to the accumulating evidence that antioxidant response pathways, with an emphasis on Nrf2, are promising targets for therapeutic interventions in Parkinson's disease, and that these can be targeted through gut bacteria.

ADHESION OF GASTRIC NON-HELICOBACTER PYLORI/HELICOBACTER SPECIES TO THE GASTRIC MUCOSA

Like other gastric NHPH species, *H. suis* expresses some *H. pylori*-like outer membrane proteins (OMPs), namely HorB and HpaA (*H. pylori* adhesin A). *In vitro* studies demonstrated that the porcine stomach expresses mucins at the surface epithelium, which resemble human MUC5AC and MUC6 mucins, and these may constitute binding sites for *H. suis*¹⁴. Structural analysis of porcine gastric mucins showed that they are large, oligomeric, and highly glycosylated structures, similar to human mucins. The major difference was at the mucin sulfation level, which is very high among porcine mucins but virtually absent in mucins of a healthy human stomach. This difference may explain the different colonisation patterns of *H. suis* in human and porcine stomachs. Additionally, *in vitro* studies have demonstrated that *H. suis* can bind to Gal β 3GlcNAc β 4Glc glycoconjugates at neutral and acidic pHs and bind negatively charged glycans at acidic pHs. Gal β 3GlcNAc β 3Gal β 4Glc structures can inhibit the binding of *H. suis* to mucins.

RELATION OF GASTRIC NON-*HELICOBACTER PYLORI* *HELICOBACTER* SPECIES TO ZOOZINOSIS

To clarify the zoonotic relation of NHPH, *Helicobacter* species were identified in human and animal samples using genus-specific PCRs and phylogenetic analysis of partial sequencing of the 16S ribosomal RNA gene¹⁵. The results revealed that *Helicobacter* species DNA was detected in 13 of 29 (44.83%) human samples. *H. pylori* was identified in two (15.38%), *H. bovis* was detected in four (30.77%), while seven remained unidentified. *H. bovis* and *H. heilmannii* were prevalent in animal samples. Phylogenetic analysis revealed bootstrapping of sequences with *Helicobacter cinaedi* in camels, *Helicobacter rappini* in sheep and humans, and *Wolinella succinogenes* in humans.

PATHOGENESIS RELATED TO ENTEROHEPATIC *HELICOBACTER* INFECTION

The anti-colorectal cancer activity of microbiota-specific T cells and colonisation of *Helicobacter hepaticus* in a mouse model showed a reduction in the burden of colorectal cancer in mice¹⁶. *H. hepaticus* is known to induce colitis in immunodeficient mice; however, in healthy mice, it has a possible antitumour effect¹⁶. *H. hepaticus* infection promotes antitumour immunity via specific T follicular helper (Tfh) cells; therefore, Tfh cell induction is a potential strategy to prevent colon cancer. *H. hepaticus* contributes to chronic hepatitis and fibrosis in mice. Cao et al¹⁷ indicated that the activation and accumulation of high-mobility group box 1, which plays a key role in chronic liver diseases, is observed in liver preneoplasia induced by *H. hepaticus* infection in mice; thus, it may serve as a marker for monitoring the surgical course of patients undergoing surgery for liver cancer. The relationship between *H. hepaticus* infection and breast carcinogenesis was analysed by Deng et al¹⁸. They found that *H. hepaticus* can translocate from the intestine to the mammary glands in *Apc^{min/+}* mice predisposed to mammary tumourigenesis. This phenomenon is accompanied by the migration of myeloid-derived suppressor cells, which promotes mammary tumourigenesis.

Another interesting study¹⁹ reported the contribution of *H. hepaticus* and *Helicobacter ganmani* to alcohol-related liver disease (ALD) using a mouse model of chronic and binge ethanol feeding. *Helicobacter* translocation to the liver was promoted in ethanol-induced mice in the aryl hydrocarbon receptor (AHR)-deficient strain. Decreased intestinal AHR levels and increased *H. hepaticus* infection have also been found in alcoholic patients¹⁹. Moreover, oral administration of AHR agonists improved ethanol-induced liver damage in mice, indicating that AHR in intestinal epithelial cells may be a novel target for the treatment of ALD¹⁹.

The effects of *H. hepaticus* infection in *Rag2^{-/-}Il10^{-/-}* mice were compared using a proteogenomic approach²⁰. This approach uses the Galaxy platform and two automated computational workflows to generate and refine a transcriptome derived FASTA database for proteogenomic analysis of mass spectrometry data. This method can be used to discover noncanonical peptides. In this study, 235 putative non-canonical peptide sequences were identified, of which 58 were verified with high confidence and 39 were validated using targeted proteomics assays.

ENTEROHEPATIC *HELICOBACTER* INFECTIONS IN HUMANS

H. cinaedi is the most prevalent enterohepatic *Helicobacter* in humans, and its infection causes bacteraemia. Several cases of *H. cinaedi* infection were reported between 2021 and 2022, all of which were identified in Japan. Matsuoka et al²¹ reported *H. cinaedi* infection in a patient with acquired haemophilia A and infectious aortic aneurysms. Takenaka et al²² reported *H. cinaedi* infection in a patient with diffuse large B-cell lymphoma. They mentioned the difficulty in distinguishing fever caused by *H. cinaedi* infection from febrile neutropenia and indicated that a lack of neutropenia is a feature of fever caused by *H. cinaedi* bacteraemia. *H. cinaedi* bacteraemia was also reported in a patient with pneumonia caused by *Legionella pneumophila*²³. In this case, both *L. pneumophila* and *H. cinaedi* were isolated from the same patient. The patient developed *H. cinaedi* bacteraemia again after discharge; therefore, bacterial translocation was suspected. *H. cinaedi* has been reported to cause intracranial subdural empyema²⁴. The pa-

tient had a history of a right chronic subdural haematoma that remained radiologically unchanged for 2 years. Although *H. cinaedi* was not isolated from either blood or purulent specimens, it was identified by PCR.

Toyoshima et al²⁵ reported a case of *H. cinaedi* infection causing endarteritis and vertebral osteomyelitis. As reported in a previous study, a difference in the detection rate of *H. cinaedi* infection between the Bactec Fx and BacT/Alert systems was also observed in this case. Aerobic blood cultures were analysed using a Bactec Fx system on day 1 of the first hospital admission, and these remained positive on day 4, while three sets of blood cultures analysed using the BacT/Alert system at the second hospital admission yielded negative results, despite no preceding antimicrobial administration.

Helicobacter bilis infection was reported in two cases of X-linked agammaglobulinemia²⁶. Both cases presented with skin infections, and *H. bilis* infection was confirmed through skin biopsy analysis, whereas no *H. cinaedi* infection was detected.

In a study²⁷ on the relationship between inflammatory bowel disease (IBD) and NHPH infections, 168 clinical samples, including 70 colonic biopsies and 98 fecal samples obtained from Iranian patients with IBD, were tested using PCR. Although *H. pylori* was detected in 12.9% and 3.1% of colonic biopsies and faecal specimens, respectively, NHPH were detected in both samples.

Attempts to detect *H. bilis* and *H. hepaticus* in 115 bile samples obtained from Japanese patients with a variety of gastrointestinal cancers, including pancreatic and biliary tract cancers, showed that 15 samples were positive by PCR targeting of the 16S rRNA or *cdtB* gene²⁸. Serum tests using whole cells as antigens were also performed on samples from patients without any evidence of *H. pylori* infection; *H. bilis* and *H. hepaticus* seropositivity was higher in the pancreatic cancer group (10/37 for *H. bilis* and 6/37 for *H. hepaticus*) than in the control group (0/13 for both *H. bilis* and *H. hepaticus*).

ENTEROHEPATIC HELICOBACTER INFECTIONS IN ANIMALS

The prevalence of *Helicobacter* spp. in dogs was tested in Iran by swabbing their rectal mucosa and performing both culture and PCR. *Helicobacter* spp. were detected in 13 samples²⁹, of which two were *H. bilis*, five were *H. heilmannii*, both gastric *Helicobacter* species, while the rest could not be identified.

H. hepaticus is one of the most prevalent pathogens in rodent laboratory facilities and can affect immunological reactions in laboratory mice. Kim et al³⁰ reported that embryo transfer is an effective method of eliminating this pathogen.

Neubert et al³¹ developed a multiplex PCR assay for the identification of *H. hepaticus*, *H. bilis*, *Helicobacter muridarum*, *Helicobacter rodentium*, and *Helicobacter typhlonius* using DNA obtained from faecal samples. The method was tested in eight different mouse facilities, and the prevalence was 57% for *H. rodentium*, 46% for *H. hepaticus*, 17% for *H. typhlonius*, 12% for *H. bilis*, but nil for *H. muridarum*.

Akhlaghi et al³² developed a highly sensitive culture method for *Helicobacter pullorum* detection. A total of 400 chicken meat samples from Semnan City, Iran were tested using this method. *H. pullorum* was detected in 163 (40.75%) samples with a sensitivity of 83% when PCR was considered the gold standard.

Novel *Helicobacter* species that infect gopher tortoises have been reported³³. Although culturing was unsuccessful, tortoise mortality was significantly correlated with this novel species.

FUNCTIONAL ANALYSIS OF PROTEINS PRODUCED BY ENTEROHEPATIC HELICOBACTER SPP.

The association between autophagy and apoptosis induced by the recombinant cytolethal distending toxin (CDT) of *H. hepaticus* was studied using an *in vitro* assay. It was found that apoptosis was induced *via* the p38 mitogen-activated protein kinase pathway by CdtB, and that apoptosis was aggravated by autophagy inhibition in mouse liver cells³⁴. Two studies by the same group focused on N-acetylated sugars, which are components of lipopolysaccharides in

Helicobacter spp.^{35,36}. The kinetic and structural analyses of BA919-RS02330 putatively encoding N-acetyltransferase of *H. pullorum* indicated that the enzyme utilises dTDP-3-amino-3,6-dideoxy-d-glucose and dTDP-3-amino-3,6-dideoxy-d-galactose as substrates and contributes to the production of 3-acetamido-3,6-dideoxy-d-glucose (or the galactose derivative) as the O-antigen of *H. pullorum*³⁴. In another study, an unusual sugar, 3-formamido-3,6-dideoxy-d-glucose, was suggested to be the O-antigen of *Helicobacter canadensis* by kinetic and structural analyses of the products of the HCAN_0198, HCAN_0204, and HCAN_0200 genes, which correspond to 3,4-ketoisomerase, pyridoxal 5-phosphate aminotransferase, and N-formyltransferase of *H. canadensis*, respectively³⁵.

Conflict of Interest

The authors declare no conflict of interest.

ORCID ID

Masahiko Nakamura 0000-0003-4893-1552, Somay Y Murayama 0000-0002-0610-1211, Emiko Rimbara 0000-0001-8847-1840.

REFERENCES

1. Segawa T, Ohno Y, Tsuchida S, Ushida K, Yoshioka M. *Helicobacter delphinicola* sp. nov., isolated from common bottlenose dolphins *Tursiops truncatus* with gastric diseases. *Dis Aquat Organ* 2020; 141: 157-169.
2. Tsukadaira T, Hayashi S, Ota H, Kobayashi N, Sekiguchi Y, Kodaira H, Matsumoto T, Horiuchi K, Negishi T, Kurahashi M. Prevalence, clinical features, and esophagogastroduodenoscopy (EGD) findings of non-*Helicobacter pylori* *Helicobacter* infection: A study of 50 cases at a single facility in Japan. *Helicobacter* 2021; 26: e12811.
3. Kadota H, Yuge R, Miyamoto R, Otani R, Takigawa H, Hayashi R, Urabe Y, Oka S, Sentani K, Oue N, Kitadai Y, Tanaka S. Investigation of endoscopic findings in nine cases of *Helicobacter suis*-infected gastritis complicated by gastric mucosa-associated lymphoid tissue lymphoma. *Helicobacter* 2022; 1: e12887.
4. Da Cunha T, Dharan M. Acute Peptic Ulcer Disease Caused by Non-*Helicobacter pylori*-*Helicobacter*. *Cureus* 2021; 13: e14993.
5. Geng C, Vemulapalli R. *Helicobacter heilmannii* Infection: Dog-Derived Dyspepsia? *Am J Med* 2021; 134: e518-e519.
6. Takigawa H, Yuge R, Masaki S, Otani R, Kadota H, Naito T, Hayashi R, Urabe Y, Oka S, Tanaka S, Chayama K, Kitadai Y. Involvement of non-*Helicobacter pylori* *Helicobacter* infections in *Helicobacter pylori*-negative gastric MALT lymphoma pathogenesis and efficacy of eradication therapy. *Gastric Cancer* 2021; 24: 937-945.
7. Naito T, Yuge R, Tanaka S, Otani R, Kadota H, Takigawa H, Tamura T, Sentani K, Yasui W, Kitadai Y, Chayama K. Gastric mucosa-associated lymphoid tissue lymphoma in conjunction with multiple lymphomatous polyposis in the context of *Helicobacter pylori* and *Helicobacter suis* superinfection. *Clin J Gastroenterol* 2021; 14: 478-483.
8. Nakamura M, Øverby A, Michimae H, Matsui H, Takahashi S, Mabe K, Shimoyama T, Sasaki M, Terao S, Kamada T, Yanaka A, Iwamoto J, Tanabe S, Tari A, Nasu S, Suzuki H, Yamagata Murayama S. PCR analysis and specific immunohistochemistry revealing a high prevalence of non-*Helicobacter pylori* *Helicobacters* in *Helicobacter pylori*-negative gastric disease patients in Japan: High susceptibility to an Hp eradication regimen. *Helicobacter* 2020; 25: e12700.
9. Yasuda T, Lee HS, Nam SY, Katoh H, Ishibashi Y, Yamagata Murayama S, Matsui H, Masuda H, Rimbara E, Sakurazawa N, Suzuki H, Yoshida H, Seto Y, Ishikawa S, Jeon SW, Nakamura M, Nomura S. Non-*Helicobacter pylori* *Helicobacter* (NHPH) positive gastric cancer. *Sci Rep* 2022; 12: 4811.
10. Morgner A, Bayerdorffer E, Meining A, Stolte M, Kroher G. *Helicobacter heilmannii* and gastric cancer. *Lancet* 1995; 346: 511-512.
11. Seike T, Murayama SY, Nakamura M, Kobayashi M. Gastric Hyperplastic Polyp with *Helicobacter suis*-infected Gastritis. *Intern Med.* 2022; doi: 10.2169/internalmedicine.7779-21. Epub ahead of print. PMID: 35110474.
12. Gorlé N, Bauwens E, Haesebrouck F, Smet A, Vandenbroucke RE. *Helicobacter* and the potential role in neurological disorders: There is more than *Helicobacter pylori*. *Front Immunol* 2021; 11: 584165.
13. Berlamont H, Bruggeman A, Bauwens E, Vandendriessche C, Clarebout E, Xie J, De Bruyckere S, Van Imschoot G, Van Wonterghem E, Ducatelle R, Santens P, Smet A, Haesebrouck F, Vandenbroucke RE. Gastric *Helicobacter suis* Infection partially protects against neurotoxicity in A 6-OHDA Parkinson's disease mouse model. *Int J Mol Sci* 2021; 22: 11328.
14. Matos R, Amorim I, Magalhães A, Haesebrouck F, Gärtner F, Reis CA. Adhesion of *Helicobacter* species to the human gastric mucosa: a deep look into glycans role. *Front Mol Biosci* 2021; 8: 656439.
15. Youssef Al, Affi A, Abbadi S, Hamed A, Enany M. PCR-based detection of *Helicobacter pylori* and non-*Helicobacter pylori* species among humans and animals with potential for zoonotic infections. *Pol J Vet Sci* 2021; 24: 445-450.
16. Overacre-Delgoffe AE, Bumgarner HJ, Cillo AR, Burr AHP, Tometch JT, Bhattacharjee A, Bruno TC, Vignali DAA, Hand TW. Microbiota-specific T follicular helper cells drive tertiary lymphoid structures and anti-tumor immunity against colorectal cancer. *Immunity* 2021; 54: 2812-24.e4.

17. Cao S, Miao J, Qian M, Zhu C, Ding S, Yin J, Zhu L, Zhang Q. *Helicobacter hepaticus* Infection Promotes the Progression of Liver Preneoplasia in BALB/c Mice via the Activation and Accumulation of High-Mobility Group Box-1. *Front Microbiol* 2021; 12: 789752.
18. Deng H, Muthupalani S, Erdman S, Liu H, Niu Z, Wang TC, Fox JG. Translocation of *Helicobacter hepaticus* synergizes with myeloid-derived suppressor cells and contributes to breast carcinogenesis. *Oncoimmunology* 2022; 11: 2057399.
19. Qian M, Liu J, Zhao D, Cai P, Pan C, Jia W, Gao Y, Zhang Y, Zhang N, Zhang Y, Zhang Q, Wu D, Shan C, Zhang M, Schnabl B, Yang S, Shen X, Wang L. Aryl Hydrocarbon Receptor Deficiency in Intestinal Epithelial Cells Aggravates Alcohol-Related Liver Disease. *Cell Mol Gastroenterol Hepatol* 2022; 13: 233-256.
20. Rajczewski AT, Han Q, Mehta S, Kumar P, Jagtap PD, Knutson CG, Fox JG, Tretyakova NY, Griffin TJ. Quantitative Proteogenomic Characterization of Inflamed Murine Colon Tissue Using an Integrated Discovery, Verification, and Validation Proteogenomic Workflow. *Proteomes* 2022; 10: 11.
21. Matsuoka A, Sasaki Y, Kubodera A, Hayashi K, Shimizu R, Toriihara A, Nakamura A, Furukawa K, Tanaka H. Acquired Hemophilia A Presenting with Infectious Aortic Aneurysms Due to an Underlying *Helicobacter cinaedi* Infection. *Intern Med* 2021; 60: 3947-3952.
22. Takenaka K, Sugimoto T, Kawamura K, Fukumoto T, Onuma K, Naito T, Oka M. Recurrent Fever due to *Helicobacter cinaedi* Infection during R-CHOP Chemotherapy in Diffuse Large B-Cell Lymphoma: Case Report and Literature Review. *Case Rep Oncol* 2021; 14: 1315-1322.
23. Nagase T, Wada S, Yokozawa T, Fujita A, Oda T. Bacteremia Caused by Both *Legionella pneumophila* Serogroup 2 and *Helicobacter cinaedi*. *JMA j* 2021; 4: 297-301.
24. Akiyama T, Imamura H, Fukui N, Sakai N. *Helicobacter cinaedi*-infected chronic subdural hematoma mimicking an expanding hematoma: A case report. *Surg Neurol Int* 2021; 12: 288.
25. Toyoshima H, Tanigawa M, Ishiguro C, Tanaka H, Nakanishi Y, Sakabe S. *Helicobacter cinaedi*-infected aneurysm and vertebral osteomyelitis in an immunocompetent patient. *IDCases* 2022; 27: e01426.
26. Romo-Gonzalez C, Bustamante-Ogando JC, Yamazaki-Nakashimada MA, Aviles-Jimenez F, Otero-Mendoza F, Espinosa-Rosales FJ, Espinosa-Padilla SE, Scheffler Mendoza SC, Durán-McKinster C, García-Romero MT, Saez-de-Ocariz M, Lopez-Herrera G. Infections With Enterohepatic Non-*H. pylori* *Helicobacter* Species in X-Linked Agammaglobulinemia: Clinical Cases and Review of the Literature. *Front Cell Infect Microbiol* 2021; 11: 807136.
27. Pirmanesh S, Mirzaei N, Azimirad M, Yadegar A, Kao JY, Aghdaei HA, Zali MR. A report of nonexistence of the non-*Helicobacter pylori* *Helicobacter* species in Iranian patients suffering from inflammatory bowel disease. *Folia Microbiol (Praha)* 2021; 66: 751-759.
28. Osaki T, Lin Y, Sasahira N, Ueno M, Yonezawa H, Hojo F, Okuda M, Matsuyama M, Sasaki T, Kobayashi S, Tezuka S, Tanaka K, Dan N, Kuruma S, Egawa N, Kamiya S, Kikuchi S. Prevalence estimates of *Helicobacter* species infection in pancreatic and biliary tract cancers. *Helicobacter* 2022; 27: e12866.
29. Fatemi Khader M, Pourmahdi Borujeni M, Moori Bakhtiari N, Avizeh R. An exploratory study on the presence of *Helicobacter heilmannii* and *Helicobacter billis* in the feces of companion dogs. *Vet Med Sci* 2022; 8: 537-545.
30. Kim H, Bang J, Baek SH, Park JH. Eliminating murine norovirus, *Helicobacter hepaticus*, and intestinal protozoa by embryo transfer for an entire mouse barrier facility. *Exp Anim* 2022; 71: 28-35.
31. Neubert V, Sadek A, Burell T, Ralsler A, Erhard M, Gerhard M, Seidel K, Kalali B. Validation and improvement of a multiplex PCR method to detect murine *Helicobacter* species in feces samples of mice. *Helicobacter* 2022; e12888.
32. Akhlaghi H, Emadi Chashmi SH, Jebelli Javan A. Development of a novel and specialized cultivation method for isolating *Helicobacter pullorum* from chicken meat. *Iran J Vet Res* 2021; 22: 76-80.
33. Desiderio TM, Stacy NI, Ossiboff RJ, Iredale M, Archer LL, Alexander AB, Heard DJ, Crevasse SE, Craft WF, Fredholm DVE, Donnelly KA, Rosenberg JF, Childress AL, Russell K, Wellehan JFX Jr. Identification of a novel mortality-associated *Helicobacter* species in gopher tortoises (*Gopherus polyphemus*), qPCR test development and validation, and correlation with mortality in a wildlife rehabilitation population. *Vet Microbiol* 2021; 259: 109136.
34. Qian M, Cao S, Wang T, Xu X, Zhang Q. Apoptosis triggered by cytolethal distending toxin B subunit of *Helicobacter hepaticus* is aggravated by autophagy inhibition in mouse hepatocytes. *Biochem Biophys Res Commun* 2022; 598: 40-46.
35. Heisdorf CJ, Griffiths WA, Thoden JB, Holden HM. Investigation of the enzymes required for the biosynthesis of an unusual formylated sugar in the emerging human pathogen *Helicobacter canadensis*. *Protein Sci* 2021; 30: 2144-2160.
36. Griffiths WA, Spencer KD, Thoden JB, Holden HM. Biochemical investigation of an N-acetyltransferase from *Helicobacter pullorum*. *Protein Sci* 2021; 30: 2418-2432.