

RESEARCH LETTER

Helicobacter pylori: foe and friend?

G. Brunner

Hannover Medical School, Institute of Toxicology, Hannover, Germany

Corresponding Author: Gorig H.G. Brunner, MD; e-mail: gorigbrunner@yahoo.de

Dear Editor,

Attending the XXXVth Workshop of the European Helicobacter & Microbiota Study Group in Glasgow, I enjoyed the high standard of research and the progress in understanding *Helicobacter pylori* (*Hp*). Listening to and looking at the presentations, I got the impression that there exists just one strain from the bacterium and one aim: how best to get rid of the bug. Aside from countless genetic variations there are at least three clearly different main strains of *Hp*. These strains are defined by the two different antigens CagA and VacA and can easily be diagnosed by an immunoassay. In our outpatients' clinic, we found 56% of the patients to be *Hp* negative and 44% *Hp* positive. Of the *Hp* positive patients were:

- 66% CagA positive/VacA negative
- 20% CagA positive/VacA positive
- 14% CagA negative/VacA negative.

In our unit, the decision for eradication of *Hp* was not made by the mere detection of the bacterium but only by the gastric history or the histological findings. I am aware that many patients are at danger from *Hp* in the stomach, the duodenum and by toxins via the vagus nerve in the brain. However, I am convinced that others may benefit from the bacterium. E.g. certain strains of *Staphylococcus* and *E.coli* can cause severe life threatening disease. Nonetheless, numerous strains of *Staphylococcus* and *E.coli* within the human microbiome are peaceful residents producing vitamin K^{1,2}. *Helicobacter* induces an immune response in the lung protecting against Asthma and it produces spermidine an important biogenic amine^{3,4}. Just as nobody claims that only a dead *Staphylococcus* is a good *Staphylococcus* and only a dead *E.coli* is a good *E.coli*, the dictum that only a dead *Helicobacter* is a good *Helicobacter* should be "eradicated".

In our patients with ulcers and acute, chronic or atrophic gastritis we found CagA and VacA in many patients; however, we also saw patients with extremely high antibody titers of CagA and VacA who never had any gastric disease or noticeable histology. It is the immune response of the patient that shows us what to do. Why use a dual antibiotic treatment when the patient does not need it, increasing the risk of antibiotic resistance. And if one is afraid that the "benign" histologic finding may later decline, why not do a control 5 to 10 years later?

The author of this letter is 83 years old. He never had gastric symptoms except for an occasional bout of reflux from a small hiatus hernia. For the last 37 years, he knows of his stomach resident *Hp*. (CagA negative/VagA negative). His histology (Figure 1) shows a mild gastritis without metaplasia or intraepithelial lymphocytosis. Maybe he benefits from the production of spermidine from his microbial resident.



This work is licensed under a [Creative Commons Attribution-NonCommercial-ShareAlike 4.0 International License](https://creativecommons.org/licenses/by-nc-sa/4.0/)

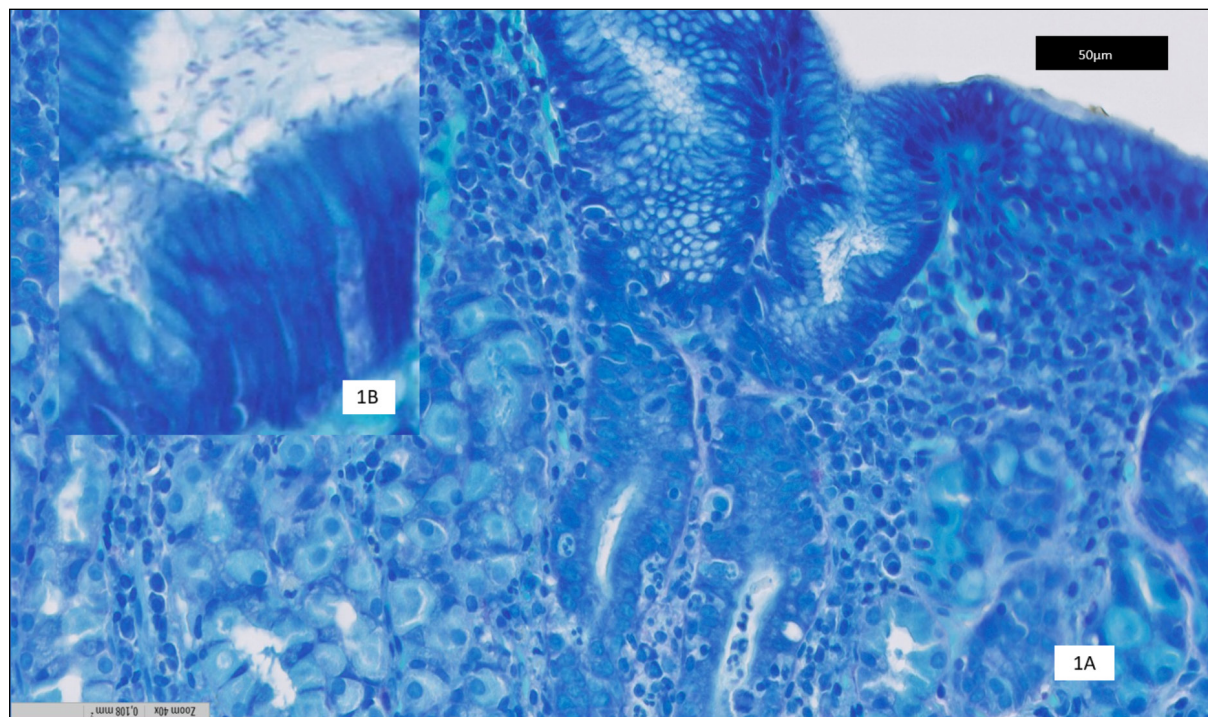


Figure 1. Chronic-active corpus gastritis (endoscopic biopsy March 2022). **A**, Gastric mucosa corpus-type with superficial inflammatory round cell infiltration of the tunica propria and neutrophilic inflammation of the foveolar neck-epithelium (center). The glands are unaltered and show normal acidophilic cells, x40. **B**, (Inset): Numerous *Hp* organisms within the mucous and attached to the surface of the foveolar cells, x100. By courtesy of Prof. Dr. Helmut Ostertag (Pathologisches Institut, Klinikum Region Hannover).

May this little note stimulate research about the pathological effects of the different *Hp* strains and their immune reactions?

Conflict of Interest

The author declares that he has no conflict of interest to declare.

REFERENCES

1. Vollins C. Distributions of menaquinones within members of the genus staphylococcus. FEMS Microbiol Lett 1981; 12: 83-85.
2. Romatar K, Conly JM, Chubb H, Louie TJ. Production of menaquinones by intestinal anaerobes. J Infect Dis 1984; 150: 213-219.
3. Velásquez RD, Brunner G, Varrentrapp M, Tsikas D, Frölich JC. Helicobacter pylori produces histamine and spermidine. Z Gastroenterol 1996; 34: 116-122.
4. Eisenberg T, Abdellatif M, Schroeder S, Primessnig U, Stekovic S, Pendl T, Harger A, Schipke J, Zimmermann A, Schmidt A, Tong M, Ruckstuhl C, Dammbroeck C, Gross AS, Herbst V, Magnes C, Trausinger G, Narath S, Meinitzer A, Hu Z, Kirsch A, Eller K, Carmona-Gutierrez D, Büttner S, Pietrocola F, Knittelfelder O, Schrepfer E, Rockenfeller P, Simonini C, Rahn A, Horsch M, Moreth K, Beckers J, Fuchs H, Gailus-Durner V, Neff F, Janik D, Rathkolb B, Rozman J, de Angelis MH, Moustafa T, Haemmerle G, Mayr M, Willeit P, von Frieling-Salewsky M, Pieske B, Scorrano L, Pieber T, Pechlaner R, Willeit J, Sigrist SJ, Linke WA, Mühlfelder C, Sadoshima J, Dengjel J, Kiechl S, Kroemer G, Sedej S, Madeo F. Cardioprotection and lifespan extension by the natural polyamine spermidine. Nat Med 2016; 22: 1428-1438.